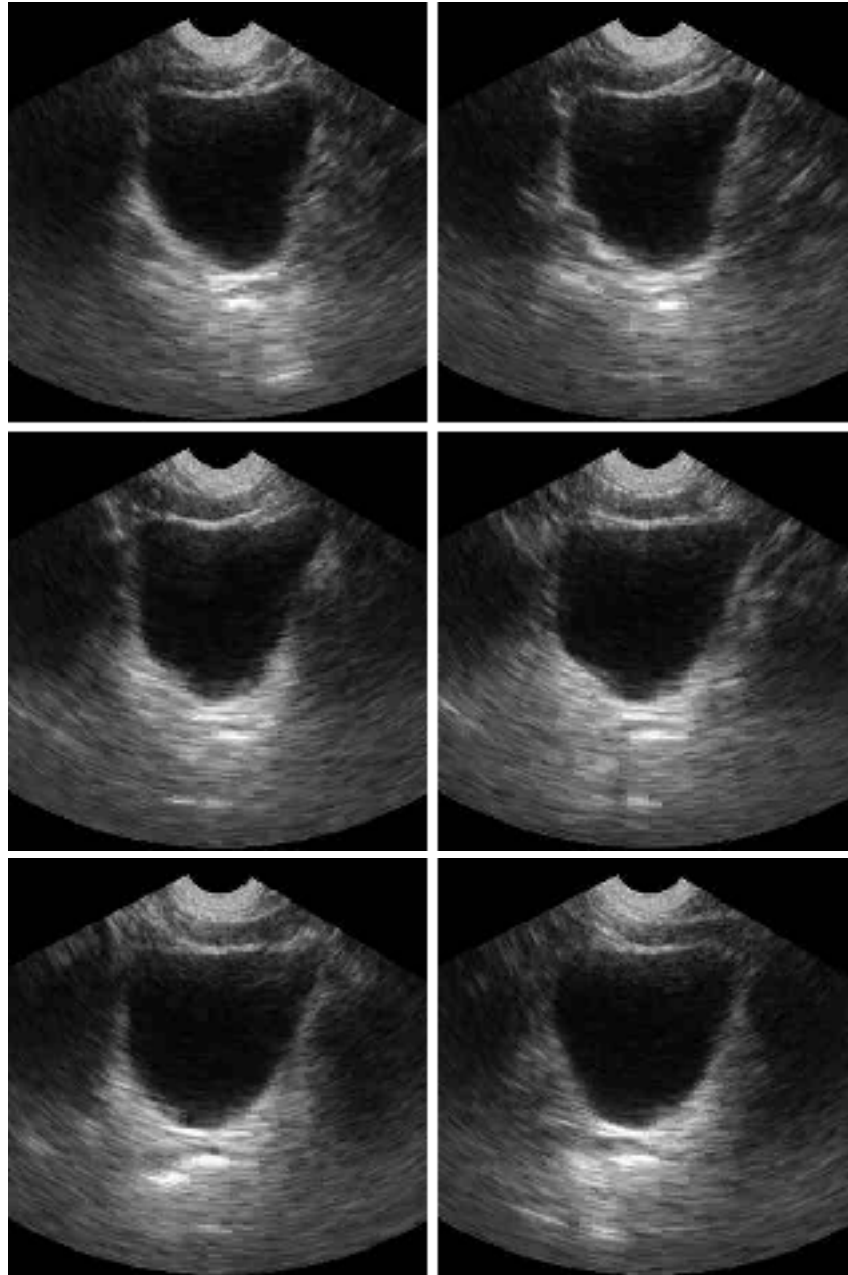


# BladderScan™ Results

---

**Date and time:** Thursday, January 23, 2003 6:15:47 PM  
**Patient ID:** 102  
**Patient Name:**  
**Operator:** Moline  
**Physician:**

**Bladder Volume:** 347 ml



**Physician Signature:** \_\_\_\_\_

# BladderScan™ Report for Physician's Office

Patient Name: \_\_\_\_\_ Scan Date / Time: **Thursday, January 23, 2003 6:15:47 PM** Bladder Volume: **347** ml  
 Patient ID: **102**

**Symptoms:**

Male  Female

- Sprayed Stream     Urgency     Frequency     Dribbling     Urinary Tract Infection  
 Hematuria     Dysuria     Nocturia     Nocturnal Enuresis     Urinary Incontinence  
 Slow Stream     Hesitancy     Other: \_\_\_\_\_

**Medical History:**

- Change in Continence Status     History of Urinary Retention     Suprapubic Pain or Discomfort  
 Diagnosis of Neurogenic Bladder     Neurologic Disease: \_\_\_\_\_  
 Recurrent UTIs     Other: \_\_\_\_\_

**Post-Op Evaluation Emptying:**

- TURP     Sling     RRP     TUIBN     SEEDS     Cryo     Cysto     PNBX     PP     SP  
 Suspension     Peri-Urethral Injs     Other: \_\_\_\_\_

**Findings:**

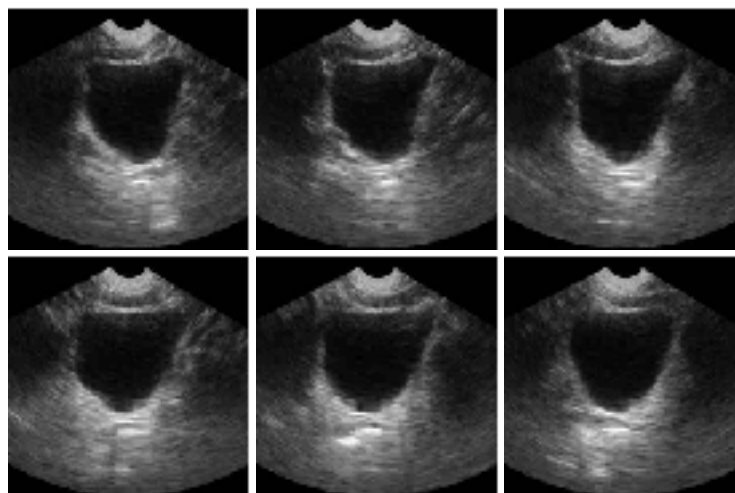
- Urine Volume WNL     Elevated Volume     Other: \_\_\_\_\_

**Impressions:**

- Urinary Retention     Incomplete Bladder Emptying     Other: \_\_\_\_\_

**Treatment Plan:**

- Indwelling Urethral Catheter     Monitor PVR  
 Intermittent Catheterization     Other: \_\_\_\_\_



Operator: **Moline**  
 Physician: \_\_\_\_\_

Physician Signature: \_\_\_\_\_